



تاریخ دریافت ۸۳/۱۰/۱۶ پذیرش مقاله ۸۴/۰۲/۲۱

Mixed

()

%

(.)

%

(.)

(.)



* *

Alkph, ()

ESR=۵۴, Hb ,

(/ cm)

(, cm)

Fat lines

Enhance

C.T (/ /)

%

Facial plane Fat line

IUD

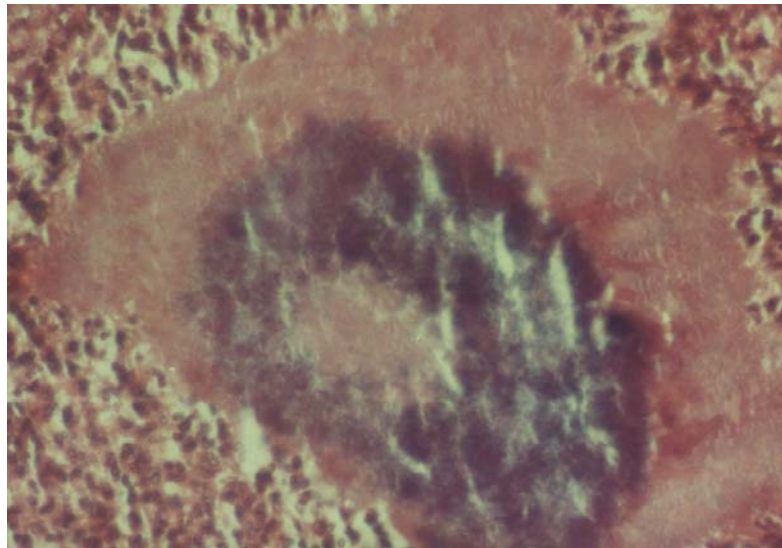
.()

* mm


Grocott



:



:



:

()

()

(.)

(.)

References:

1. Mandel G: principles and practice of infectious diseases. 5th Ed, Edinburgh, Churchill Livingstone, 2000: 2648.
2. Kasano Y: Hepatic actinomycosis infiltrating diaphragm and right lung. Am J Gastroenterol, 1996, 91: 2418 – 2420.
3. Chan P M Y: Splenic actinomycosis. J R coll surg Ed, 1999, Oct (44): 344-5.
4. Marcella V K, et al: Pelvic actinomycosis: Urologic perspective. Int Braz J Urol, 2004, sep-
oct; 30(5): 3, 67-76.
5. Ruutu P, et al: Hepatic actinomycosis presenting as repeated cholestatic reactions.scand J infect Dis, 1982, 14: 235 –238.
6. Miyamoto M I, Fang F C: pyogenic Liver abscess involving actinomyces: case report and review. Clin Infect Dis, 1993, 16: 303 -309.
7. Leow C K: Soft-tissue images: Abdominal actinomycosis. Can J surg, 2000, Feb; 43(1): 10-15.