



تاریخ دریافت ۸۳/۱۰/۲۳، پذیرش مقاله ۸۴/۰۳/۲۴

× / ×

intensity MRI

T₂-weighted

()

()

()

()

()

()

⁶ Steeper

⁷ Rosai

strogen receptor Vimentin, Smooth muscle actin
Progesterone receptor Desmin,S-100 protein

(.)

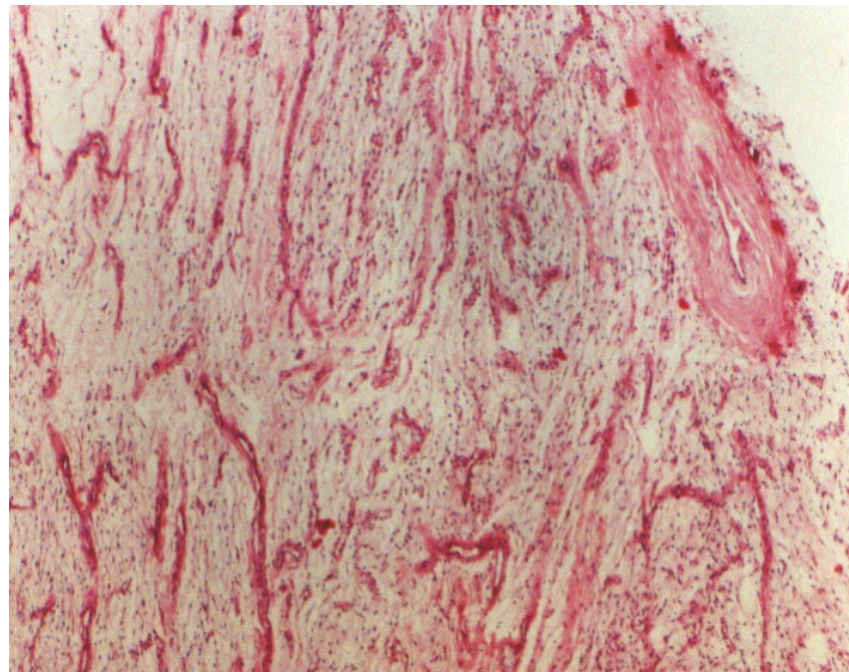
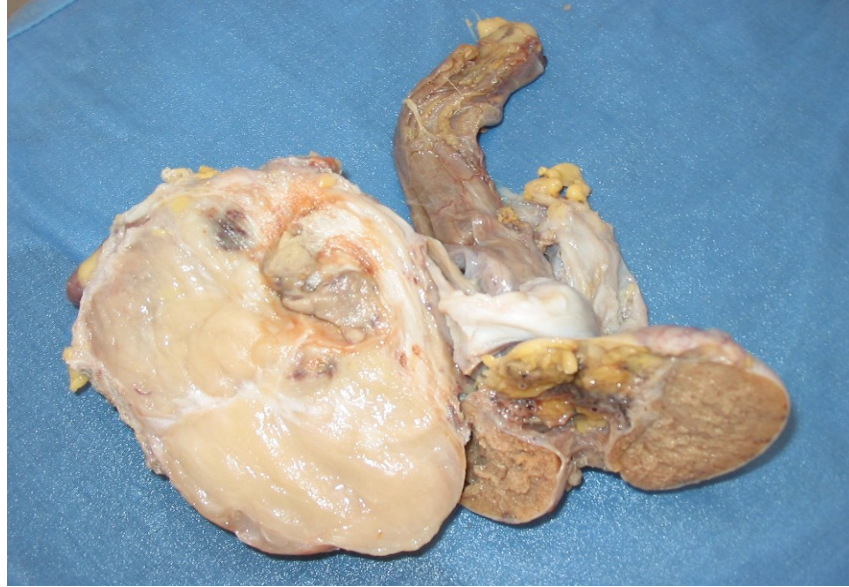()

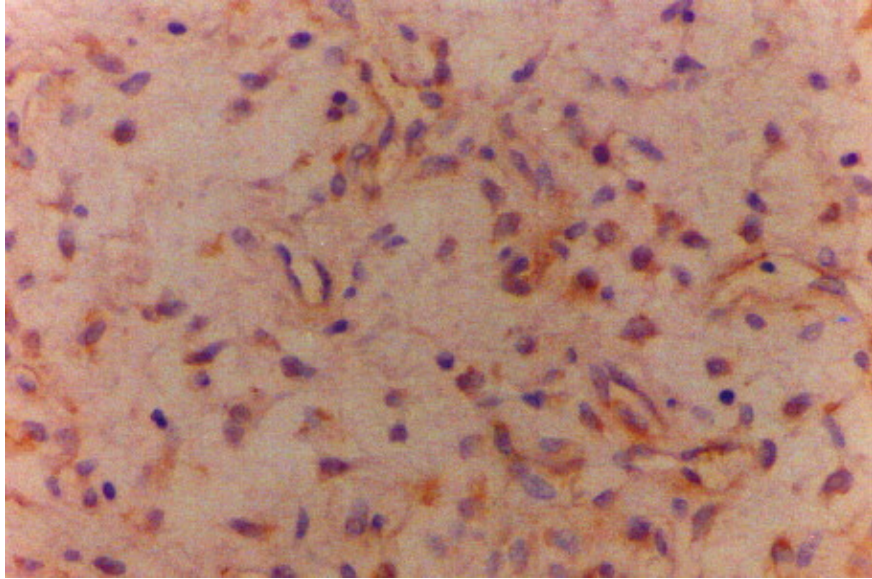
x / x

)

(.

x / x /





:

:

| ⁷ PR | ⁶ ER | ⁵ S-100 | SMA | | | | |
|-----------------|-----------------|--------------------|-----|--|-----|---|--------------------------|
| / | / | | | | () | | Enzinger and Weiss |
| | | | () | | () | | Granter, S.R et al. |
| | | | | | | | William Y.W.Tsang et al |
| | | | () | | () | | Julia C.Iezzoni et al |
| | | | | | | (| Hirofume Nakayama et al. |

¹ Mouse Anti-Vimentin, DAKO Corporation
² Mouse Anti-Human Desmin D33, DAKO Corporation
³ Rabbit Anti-Keratin (Wide Spectrum Screening), DAKO Corporation
⁴ Mouse Anti-Human Alpha-Smooth Muscle Actin, DAKO Corporation
⁵ Rabbit Anti-S-100, DAKO Corporation
⁶ Mouse Antibody Prediluted clone: 1D5, Cell Marque Corporation
⁷ Mouse Antibody prediluted clone: hPRa2+3, Cell Marque Corporation

References:

1. Weiss S W, Goldblum J R: Enzingers and Weiss's soft tissue tumors. 4th Ed, Philadelphia, Mosby-Year Book Inc, 2001: 1444-1453.
2. Rosai J: Ackerman's Surgical Pathology. 8th Ed, Philadelphia, Mosby-Year Book Inc, 2004:1477.
3. Outwater E K, Marchetto B E, Wagner B J, Siegeman E S: Aggressive Angiomyxoma: Findings on CT and MR imaging. A J R, 1999, 172: 435-438.
4. Iezzoni J C, Fechner R E, Wong L S, Rosai j: Aggressive Angiomyxoma in Males: A Report of Four Cases. Am J Clin Path, 1995, 104: 391-396.
5. Nakayama H, Hiroi M, Kiyoku H: Naruse K, Enzan H. Superficial Angiomyxoma of the Right Inguinal Region: Report of a Case. Jpn J Clin Oncol, 1997, 27: 200-203.
6. Tsang W Y W, Chan J K C, Lee K C, Fletcher C: Aggressive Angiomyxoma: A Report of Four Cases Occurring in Men. Am J Surg Pathol, 1992, 16: 1059-1065.
7. Hong R D, Outwater E, Leonard G: Aggressive Angiomyxoma of the Perineum in a Man. J Urol, 1997, 157: 959-960.
8. Granter S R, Nucci M R, Fletcher C: Aggressive Angiomyxoma: reappraisal of its relationship to angiomyo fibroblastoma in a series of 16 cases. Histopathology, 1997, 30: 3-10.
9. Clatch R J, Drake W K, Gonzalez J G: Aggressive Angiomyxoma in men: A report of 2 cases associated with inguinal hernias. Arch Pathol Lab Med, 1993, 117: 911-913.