

E-mail: ar-alaee@yahoo.com

// : // : // :

Čq ( )

( ) ( ) ( ) ( ) ( ) ( ) ( ) ( ) ( ) ( )

( ) ( ) ( ) ( ) ( ) ( ) ( ) ( ) ( ) ( )

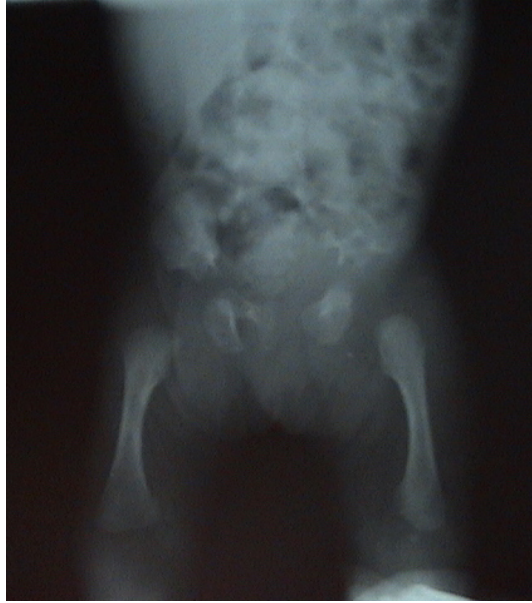( ) ( ) ( ) ( ) ( ) ( ) ( ) ( ) ( ) ( )

( ) ( ) ( ) ( ) ( ) ( ) ( ) ( ) ( ) ( )

/÷

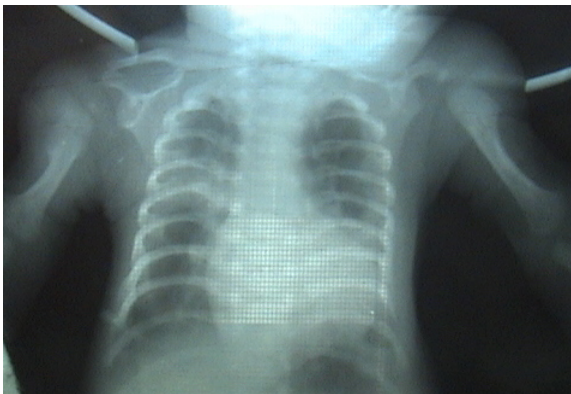
( ) ( ) ( ) ( ) ( ) ( ) ( ) ( ) ( ) ( )

( ÷ )



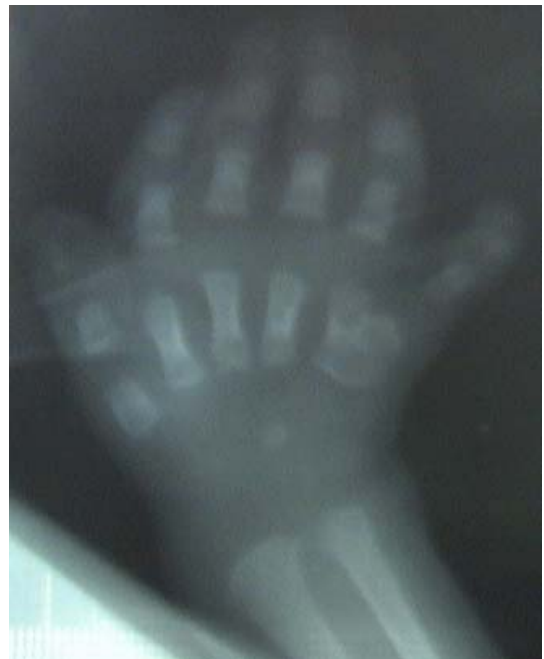( )

( ) ( )  
 ( )



÷


( )



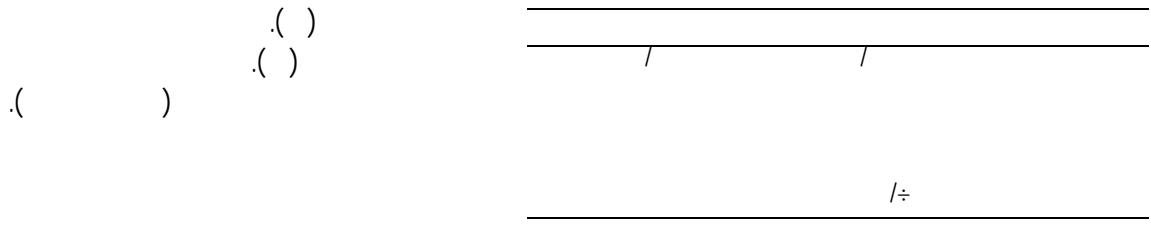
, Post axial

- 
- |                           |  |
|---------------------------|--|
| 1. CloverLeaf skull       | 3. Asphyxiating Thoracic dysplasia       |
| 2. Handle-bars of bicycle | 4. Thoracic- Pelvic phalangeal dysplasia |

:



( ÷ ÷ )



( )

( )

( ÷ )

( )  
 6

( )

( )

( ÷ )

( )

Čq

( ÷ )

( ÷ )

- 
- |                                    |                          |
|------------------------------------|--------------------------|
| 1. Ultra structure                 | 5. Hook or spur          |
| 2. Bellshape                       | 6. Triradiat             |
| 3. Short rib polydactyly syndromes | 7. Trident configuration |
| 4. Skeletal survey                 |                          |



## Reference

- Hagen-Ansert SL. Text book of diagnostic ultrasonography 5th ed. st. louis: MOSby; 2001; p: 927.
- Yerian LM, Brady L, Hart J. Hepatic manifestations of Jeune syndrome (asphyxiating thoracic dystrophy). *Semin Liver Dis.* 2003; 23(2): 195-200
- Dettrson H, Elligon D. The Encyclopaedia of Medical Imaging. 5th ed, RSNA. 2001; 220(1); 12.
- Sutton D. Text book of rad and imaging 7th ed. New york churchill living stone, 2003; PP: 28-29.
- Callen PW, Ultrasonography in obstetric and gynecology. 4th ed. New york: W.B. saunders. 2000; P: 272-3.
- Mcgahan J, Goldberg B, Diagnostic ultrasound, Philadelphia, lippincott - Raven 2000; P: 480.
- Behrman R, Nelson text book of pediatrics. 16th ed. New york W.B sanders 2000; P: 1468 .
- Campbell .M – FORFAR. Text book of pediatrics . churchill living stone New york , 1998. P.793.
- Capilupi B, Olappi G, Cornaglia AM, [Asphyxiating thoracic dysplasia or Jeune's syndrome. Description of 2 mild familial cases] *Pediatr Med Chir.* 1996; 18(5): 529.
- Hollander NS, Robben SG, Hoogeboom AJ, Early prenatal sonographic diagnosis and follow-up of Jeune syndrome. *Ultrasound Obstet Gynecol.* 2001; 18(4): 378-83.
- Whitley CB, Schwarzenberg SJ, Burke BA, Direct hyperbilirubinemia and hepatic fibrosis: A new presentation of Jeune syndrome (asphyxiating thoracic dystrophy). *Am J Med Genet* 1987; Suppl 3: 211-20.
- Poggiani C, Gasparoni MC, Asphyxiating thoracic dysplasia in a lethal form: radiological and sonographic findings. *Minerva Pediatr.* 2000; 52(1-2): 63-7. English, Italian.
- Spranger W, Brill PW, Poznanski AK. Bone dysplasia, 2ed ed. Oxford, fischer verlag. 2002; PP:125-130.
- Murray RO, jacobson HG, Stoker DJ. The radiological of Skeletal disorders. 3rd ed, london, churchill livingstone 1990; P: 134.
- Silverman F, Baker D, berdon WE, Dorst J, Girdany BR, LEE F. Caffy's pediatric X-ray diagnosis; 9th ed. Chicago : year book medical publishers. 1993; P: 1590.
- Chen CP, Lin SP, Liu FF, Prenatal diagnosis of asphyxiating thoracic dysplasia (Jeune syndrome). *Am J Perinatol.* 1996;13(8): 495-8.
- Ben Ami M, Perlitz Y, Haddad S, Matilsky M. Increased nuchal translucency is associated with asphyxiating thoracic dysplasia. *Ultrasound Obstet Gynecol.* 1997; 10(4): 297-8.
- Vanhoenacker FM, Van de Perre, Asph S. thorac. dys. *BTR.* 2004 Jan; 87(1)
- Yang SS, Heidelberger KP, Brough AJ, Lethal short-limbed .Chondrodysplasia in early infancy. *Perspect Pediatr Pathol.* 1976; 3: 1-40.
- Slomic A, Bouliane R. [Bone maturation in asphyxiating thoracic dysplasia and diastrophic dwarfism in the neonatal period (author's transl)] *J Radiol Electrol Med Nucl.* 1977; 58(1): 17-20. French.
- Yang SS, Langer LO Jr, Cacciarelli A, Three conditions in neonatal asphyxiating thoracic dysplasia (Jeune) and short rib-polydactyly syndrome spectrum: a clinicopathologic study. *Am J Med Genet.* 1987; Suppl 3: 191-207.
- Nogami H, Oohira A, Ozeki K, Ultrastructure of cartilage in heritable disorders of connective tissue. *Clin Orthop.* 1979; (143): 251-9.
- Morgan NV, Bacchelli C, Gissen P, A locus for asphyxiating thoracic dystrophy, ATD, maps to chromosome 15p13. *J Med Genet.* 2003; 40(6): 431-5.
- Kajantie E, Andersson S, Kaitila I. Familial asphyxiating thoracic dysplasia: clinical variability and impact of improved neonatal intensive care. *J. Pedia.* 2001; 139(1): 130-3.
- Panero Lopez AL, Puyol Buil PJ. Asphy. thoracic dys. In 2 dizygotic twins , *Ann Gene.* 1987; 3.(2) : 113 – 7 . spanish.
- Mortier .G.The diagnosis of skeletal dysplasias : a multidisciplinary approach.*European J. of Rad* (2001) 40, 161-167. Belgium.
- Torbus O, Jachimowicz M, Grzybek H,[Asphyxiating thoracic thoracic dysplasia (Jeune's Syndrome) in 15-years-old boy—6 years of observation] *Wiad Lek.* 2002;55(9-10):635-43. Polish.
- Brunger HJ, Natzschka J.[Asphyxiating thoracic dystrophy (author's transl)] *Klin Padiatr.* 1977; 189(2): 191-7. German.

29. SwiSchuk LE. Imaging of the newborn, infant, and young child. 3th ed. Galoston: churchill living stone., 1989; PP: 891-892.
30. Bernstein J, Brough AJ, The renal lesion in syndromes of multiple congenital malformations. Cerebrohepatorenal syndrome; Jeune asphyxiating thoracic dystrophy; tuberous sclerosis; Meckel syndrome. Birth Defects Orig Artic Ser. 1974;10(4):35-43.
31. Benallegue A, Lacete F, Maroteaux P. [Cloverleaf skull associated with generalized bone defects close to asphyxiating thoracic dysplasia] Ann Genet. 1987;30(2):113-7. French.
32. Masuno M.[Asphyxiating thoracic dysplasia] Ryoikibetsu Shokogun Shirizu. 2001; (33): 232-3. Japanese.
33. Harms K, Klinge O, Speer CP. [Variability of Jeune syndrome. Lung hypoplasia, renal failure and direct hyperbilirubinemia in a newborn infant] Monatsschr Kinderheilkd. 1993; 141(11): 868-73. German.
34. Reiterer F, Muller WD, Wendler H. [Variance in the clinical picture and course of asphyxiating thoracic dysplasia (Jeune syndrome)] Klin Padiatr. 1986; 198(4): 340-3. German.
35. Marti E, Botey J, Marin A, [Jeune syndrome and fungal bronchial asthma] Allergol Immunopathol (Madr). 1982; 10(2): 131-6. Spanish.
36. Edelson PJ, Spackman TJ, Belliveau RE, A renal lesion in asphyxiating thoracic dysplasia. Birth Defects Orig Artic Ser. 1974; 10(4): 51-6.
37. Kozlowski K, Masel J, Morris L, Neonatal death dwarfism. (A further report). ROFO Fortschr Geb Rontgenstr Nuklearmed. 1978; 129(5): 626-33.
38. Giedion A. Phalangeal cone shaped epiphysis of the hands (PhCSEH) and chronic renal disease—the conorenal syndromes. Pediatr Radiol. 1979;8(1):32-8.
39. Skiptunas SM, Weiner S. Early prenatal diagnosis of asphyxiating thoracic dysplasia (Jeune's syndrome). Value of fetal thoracic measurement. J Ultrasound Med. 1987; 6(1). 41-3.
40. Vanhoenackerf, Hul W, Congenital skeletal abnormalities: an introduction to the radiological semiology. .European J. of Rad 40 (2001) 168-183. Belgium.
41. Kradow D, Salazar D, Wilcox WR, Exclusion of the Ellis-van Creveld region on chromosome 4p16 in some families with asphyxiating thoracic dystrophy and short-rib polydactyly syndromes. Eur J Hum Genet. 2000; 8(8): 645-8. Asphyxiating thoracic dysplasia in a lethal form: radiological and sonographic findings. Minerva Pediatr. 2000; 52(1-2): 63-7. English, Italian.
42. Nagai T, Nishimura G, Kato R, Del(12)(p11.21p12.2) associated with an asphyxiating thoracic dystrophy or chondroectodermal dysplasia-like syndrome. Am J Med Genet. 1995; 55(1): 16-8.
43. Katthofer B. [Asphyxiating thoracic dysplasia (Jeune-syndrome)--a medical and nursing report] Kinderkrankenschwester. 1993; 12(10): 342-4. German.
44. Hopper MS, Boultee JE, Watson AR. Polyhydramnios associated with congenital pancreatic cysts and asphyxiating thoracic dysplasia. A case report. S Afr Med J. 1979; 56(1): 32-3.
45. Novakovic I, Kostic M, [Jeune's syndrome(3 case reports) Srp Arth Celok Lek. 1996; 124 Suppl 1: 244-6
46. Shah KJ. Renal lesion in Jeune's syndrome. Br J Radiol. 1980; 53(629): 432-6
47. Oberklaid F, Danks DM, Mayne V, P. Clinical, radiological, and pathological information on 10 patients. Arch Dis Child. 1977; 52(10): 758-65.
48. Trabelsi M, Hammou-Jeddi A, Kammoun A, [Asphyxiating thoracic dysplasia associated with hepatic ductal hypoplasia, agenesis of the corpus callosum and Dandy-Walker syndrome] Pediatrie. 1990; 45(1): 35-8. Review. French.  
[Asphyxiating thoracic dysplasia in 2 dizygotic twins] An Esp Pediatr. 1987; 26(6): 453-6. Spanish.
49. Esmer C, Alvarez-Mendoza A, Liver fibrocystic disease and polydactyly: proposal of a new syndrome. Am J Med Genet. 2001; 101(1): 12-6
50. Morrissy R Lovell and Winter. Ped. or thopaedic . 2th ed. Philadelphia Lippincott – Raven. 1996; P: 450.
51. Calver D, Keast-Butler J, Taylor D. The extra digit. A pointer to the eye? Trans Ophthalmol Soc U K. 1981; 101(1): 35-8.
52. Doraw B, Favre R. Prenatal sonographic diag. Of skeletal dys. A report of 47 cases. Annales de Genetic (2000); 43: 163-169 France.
53. Hsieh YY, Hsu TY, Lee CC, Prenatal diagnosis of thoracopelvic dysplasia. A case report. J Reprod Med. 1999; 44(8): 737-40.
54. Chen CP, Lin SP, Prenatal diagnosis of asphyxiating thoracic dysplasia (Jeune syndrome). Am J Perinatol. 1996; 13(8): 495-8. Italian.
55. Schinzel A, Savoldelli G, Briner J, Prenatal sonographic diagnosis of Jeune syndrome. Radiology. 1985; 154(3): 777-8.
56. Lipson M, Waskey J, Rice J, Prenatal diagnosis of asphyxiating thoracic dysplasia. Am J Med Genet. 1984; 18(2): 273-7.
57. Kappor R, Saha MM, Gupta NC. Antenatal diagnosis of asphyxiating thoracic dysplasia. Indian Pediatr. 1989; 26(5): 495-7
58. Sharony, Reuven; Browne, Diagnosis of the Skeletal Dysplasias. American Journal of Obstetrics & Gynecology. 1993; 169(3): 668-675.
59. Cortina H, Beltran J, Olague R, Ceres L, Alonso A, Lanuza A. Related Articles Links The wide spectrum of the asphyxiating thoracic dysplasia. Pediatr Radiol. 1979; 8(2): 93-9.