

**zorooft@ut.ac.ir**

**m.gity@sina.tums.ac.ir**

**aryan\_deldari@yahoo.com**

**ahmadian@sina.tums.ac.ir**

---

**CAD**

**CAD**

**(RCC, RML0, LCC, LMLO)**

**CAD**

**CAD**

**CAD :**

---

\*

CAD

CAD

PACS

% %

DICOM

CAD

CAD

GB

MB

micron

( )

CAD

[ ]

CAD

CAD

CAD

CAD

<sup>1</sup> Intera observer variability

<sup>2</sup> Inter observer variability

<sup>3</sup> Computerized Aided Diagnosis

<sup>4</sup> Picture and Archival Communications System

<sup>5</sup> Digital Imaging & Communication Medicine

<sup>6</sup> Left & Right-Crania Caudal (CC)- Right & Left-Media Lateral-Oblique

[ ]

CAD :

[ ]

:

)

(

[ ]

( × × × )

( × × × )

[ ] (ROI)

:

---

<sup>7</sup> Region of Interest  
<sup>11</sup> Flip  
<sup>15</sup> Wavelet and Fuzzy  
<sup>19</sup> Report

<sup>8</sup> Thumbnail  
<sup>12</sup> Histogram-Equalization  
<sup>16</sup> Visual C 6.5  
<sup>21</sup> Information

<sup>9</sup> Clipboard  
<sup>13</sup> Sobel, Canny, Laplacian and Gussian Filters  
<sup>17</sup> Access  
<sup>22</sup> Template

<sup>10</sup> Window Level  
<sup>14</sup> Kernel  
<sup>18</sup> Search

MammoCADSoft - Patient Information

File Setting Record Window

Patient Information

General Information

Patient ID: 214642788    First Name: Masumeh    Last Name: Dabir    Age: 76    Date: 2004-06-16\_20-03-59    Modality: mammo    Previous work: sono

Address: saadat abad st., No.15    Phone: 09123146517    Location: tehran    Referring Physician: Dr.Nazari

Patient

Patients' List

Number	Reception ID	First Name	Last name	Age	Date	Present Modality	Previous Work
1	214642788	Masumeh	Dabir	76	2004-06-16_20-03-59	mammo	sono
2	216750390	pooneh	derakhshan	NA	2004-06-16_20-03-40	NA	NA
3	216750390	pooneh	derakhshan	25	2004-06-09_20-54-56	mammo	sono
4	216750390	susan	hashemi	42	2004-06-09_20-53-10	mammo	mammo
5	216750389	masoumeh	hajj	79	2004-06-09_20-53-09	NA	NA
6	215615439	poonehgg	derakhshan	24	2004-05-26_17-45-53	NA	NA
7	215615434	maryam	zare	75	2004-05-26_17-37-14	mammo	NA
8	215615427	maryam	zare	49	2004-05-26_17-37-07	mammo	NA
9	214644000	Susan	Taslimi	61	2004/05/15-11:46:40	Mammo	NA
10	214642788	Masumeh	Dabir	73	2004/05/15-11:45:51	NA	NA
11	214643929	fahimeh	noorbakhsh	50	2004/05/15-11:45:29	sono	sono
12	214643926	Zahra	Rahaei	59	2004/05/15-11:45:26	sono	sono
13	213967544	sima	darabi	23	2004/05/07-15:58:21	mammo	NA

Image

View

Search

Select Item:

ID   

First   

Last

Date

Report: 214642788-2004-06-16\_20-03-59.txt - Notepad

----- Patient Information -----  
 Name:Masumeh surname:dabir Age:NA Referring-Physician: NA  
 ----- Case Report -----  
 M5  
 Bilateral Mammography:  
 dense glandular tissue and scattered puctate macrocalcifications are  
 seen in both breasts.  
 Follow up mammogram in 1-2 yrs recommended.

The image displays two windows from the MammCAD software. The top window, titled "Patient Information", is divided into three sections: "General Information", "Clinical Information", and "Case Report".

**General Information:**

Patient ID	First Name	Last Name	Age	Date	Modality	Previous work
214642788	Masumeh	Dabir	76	2004-06-16_20-03-59	mammo	sono

Address: saadat abad st., No.15  
Phone: 09123146517  
Location: tehran  
Referring Physician: Dr.Nazari

**Clinical Information:**

Complaint	Duration of Disease	Age of Meno	HRT	Breast Cancer History
HRT	Week: 0 Month: 0	Menorch: NA Menopause: NA	History After Menopause: Yes Type: Est.+Prog.	Relatives: Mother Age: Post Menopause

Pregnancies: 0

**Surgery #1-4:**

Surgery #	Date	Side	Path.
#1	2.2.2001	Right	Malignant
#2	3.7.2003	Right	Malignant
#3	1.4.2004	Left	Malignant
#4	NA	NA	NA

Digitizer Info: Model: NA, Sampling rate: NA, Grey Levels: NA, Optical Density: NA

Pathology Result: invasive lobular carcinoma  
ACR Code: NA  
Alive: NA

Buttons: Modify, Save

**Case Report:**

Template: M5Bilateral Mammography:Dense glandular tissue and scattered puctate macrocalcifications are seen in both breasts.Follow up mammogram in 1-2 yrs recommended.

The bottom window, titled "Please select required report template:", shows a grid of report templates:

Report #	Content
#1	M5Bilateral Mammography:Dense glandular tissue and scattered puctate macrocalcifications are seen in both breasts.Follow up mammogram in 1-2 yrs recommended.
#2	
#3	
#4	
#5	
#6	
#7	
#8	
#9	
#10	
#11	
#12	
#13	
#14	
#15	
#16	

Buttons: OK, Cancel

MammCAD

**Please modify patient clinical information**

Complaint

Routine CH/U

HRT

Pain

Lump

Secretion

Skin/nip retraction

HRT History After Menopause

Yes

No

HRT Type

Est.

Est.+Prog

Prog.

Cortin

Intemit

Side

Left

Right

Both

History of breast radiology

Yes

No

Breast Cancer In Relatives

Mother

Age

Pre Menopause

Post Menopause

History of breast radiology

Yes

No

Pathology Result of Surgery

invasive ductal carcinoma

insitu ductal carcinoma

invasive lobular carcinoma

insitu lobular carcinoma

proliferative changes without atypia

proliferative changes with atypia

nonproliferative changes

OK

Cancel

Surgery

Surgery #

Surgery1

Surgery2

Surgery3

Surgery4

Side

left

Right

Both

Pathology

Benign

Malignant

**Import Image**

Import/Replace Images

CCL	<input type="text" value="214642788-2004-06-19_21-05-09-CCL.bmp"/>	<input type="button" value="Reset CCL"/>
CCR	<input type="text" value="NA"/>	<input type="button" value="Reset CCR"/>
MLOL	<input type="text" value="NA"/>	<input type="button" value="Reset MLOL"/>
MLDR	<input type="text" value="NA"/>	<input type="button" value="Reset MLDR"/>
Image05	<input type="text" value="NA"/>	<input type="button" value="Reset Image05"/>
Image06	<input type="text" value="NA"/>	<input type="button" value="Reset Image06"/>
Image07	<input type="text" value="NA"/>	<input type="button" value="Reset Image07"/>
Image08	<input type="text" value="NA"/>	<input type="button" value="Reset Image08"/>

OK

Cancel

**Select Image File:**

Look in:

- 00-Phantom.bmp
- 01-Brain01.bmp
- 02-Brain02.bmp
- 03-BreastB.bmp
- 04-BreastRB.bmp
- 05-Breast-112.bmp
- 06-Breast-56.bmp

File name:

Files of type:

Open

Cancel

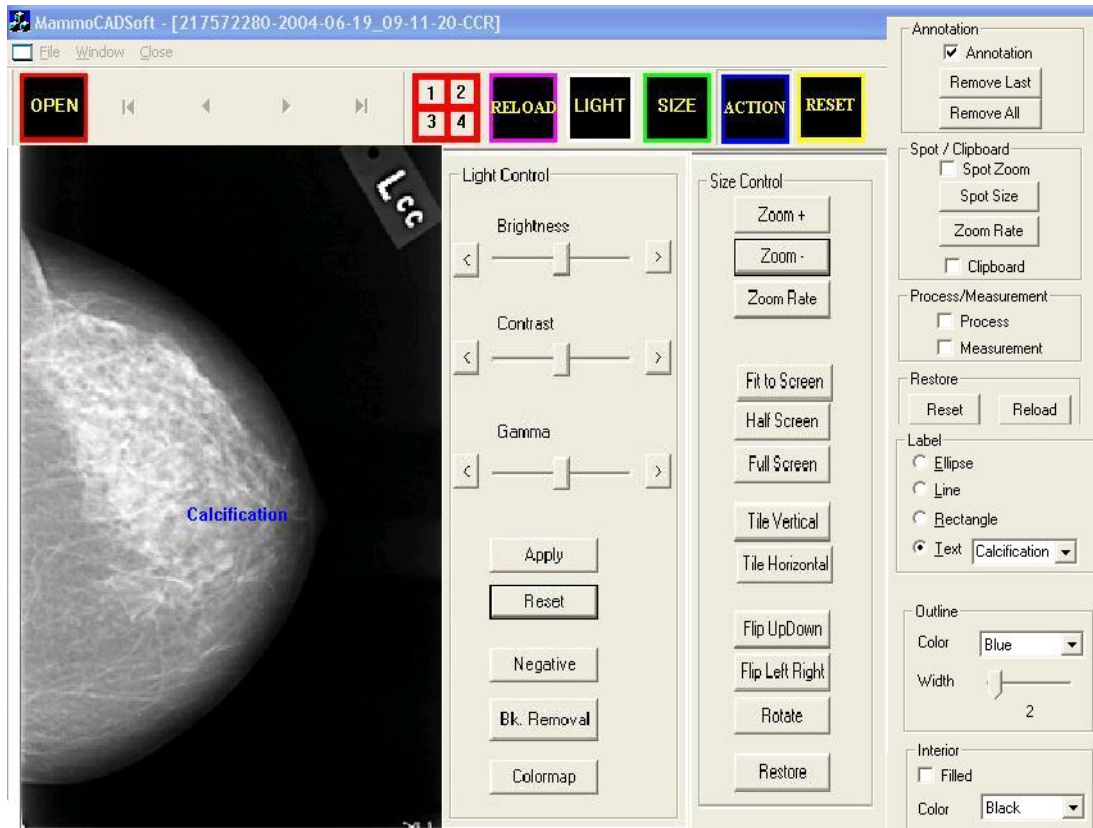
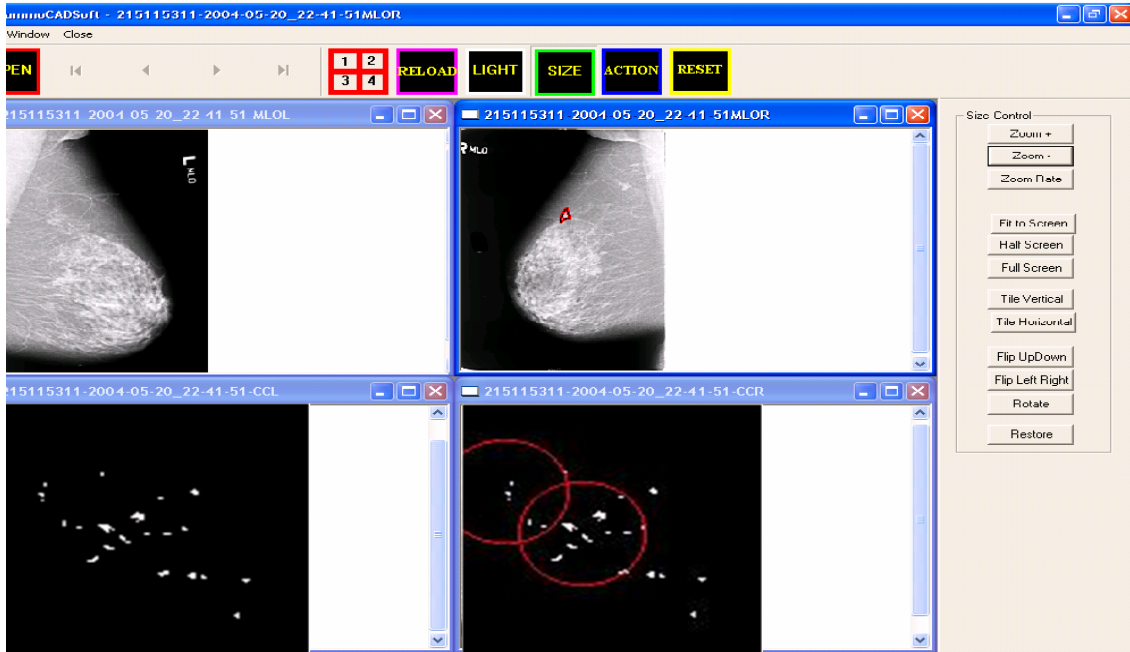
**Import Image**

Import/Replace Images

CCL	<input type="text" value="NA"/>	<input type="button" value="Reset CCL"/>
CCR	<input type="text" value="NA"/>	<input type="button" value="Reset CCR"/>
MLOL	<input type="text" value="NA"/>	<input type="button" value="Reset MLOL"/>
MLDR	<input type="text" value="NA"/>	<input type="button" value="Reset MLDR"/>
Image05	<input type="text" value="NA"/>	<input type="button" value="Reset Image05"/>
Image06	<input type="text" value="NA"/>	<input type="button" value="Reset Image06"/>
Image07	<input type="text" value="NA"/>	<input type="button" value="Reset Image07"/>
Image08	<input type="text" value="NA"/>	<input type="button" value="Reset Image08"/>

OK

Cancel



DICOM

CAD

iCAD

CAD<sub>x</sub>

---

CAD

R2-TECNOLOGY

CAD

R2-TECNOLOGY .

CAD

CAD

CAD

Pen Rad

Pen Rad

CAD

CAD

MRS

(ACR)

[ ]

CAD

PACS

:

)

(

---

<sup>27</sup> Second Pair of Eyes  
<sup>30</sup> Conventional  
<sup>33</sup> Database for Patient Information  
<sup>36</sup> Voice Reporting

<sup>28</sup> Mammography Reporting System, Inc  
<sup>31</sup> Viewer  
<sup>34</sup> Image Processing

<sup>29</sup> American College of Radiology  
<sup>32</sup> Reporting system  
<sup>35</sup> Screening- Mammography



- [5] Sickles A., Mammographic Detectability of Breast Micro Calcifications; AJR 1982.
- [6] Spiesberger W., Mammogram Inspection by Computer", IEEE transaction Imaging, 1993: 461- 465.
- [7] Maria k., Image segmentation in digital Mammography Computerized, Med Imaging and graphics, 1992; 16(5): 323- 331.
- [8] Bottigi, U., The CALMA Computer Aided Detection for Mammography, 3 rd International Workshop on Radiation Imagin Cancer, ITBS 2005: pp 88
- [9] Altman, D.G., Pructical Statistics for Medical Research, Chapman and Hall, 1991
- [10] Warren- Burhenne L.J., Wood S A., D' orsi C.J., etal. Potential Contribution of Computer- aided detection to the Sensitivity of screening Mammograh, Radiology 2000; 215: 554- 562.

[ ]

"

"

- [12] Wu Y., Doi K., Giger M.L., and Nishikawa R.M., Computerized Detection of clustered Micro Calcifications In Digital Mammograms: Applications of Artificial Neural Networks, Med. Phys, 1992; 19 (3): 555- 562.
- [13] Wang T.C. and Karayiannis N.B., Detection of Micro Calcifications in Digital Mammograms Using Wavelets, IEEE TRANSACTION ON MEDICAL IMAGING ; AGUST 1998: pp. 498- 509.
- [14] Mammography Reporting System (MRS); <http://www.mrsys.com>.
- [1] Landis S. H., Cancer Statistics. Cancer Journal for Clinicians, 1998; 48: 6- 29.
- [2] Schmidt. R. A, Clinical Use of Digital Radiography: The presents and prospects. Digital Imaging 1995;8:74-79.
- [3] Chan, H. P, Doi, k., Simranjit, G., Voyborny, c., MacMahon, J. H, and Jokich, P. M., " Image Feature Analysis and Computer- Aided Diagnosis on Digital Radiology I: Automated Detection of Micro Calcifications in Mammography", Med. Phys, 1987; 14: 538- 548.
- [4] Songyang Y., Gaun L., A CAD System for Automatic Detection of Clustered Micro Calcifications in Digitized Mammogram Films; IEEE TRANSACTION ON MEDICAL IMAGING , 2000; 19(2): 115- 125.